

American Journal of Sports Medicine

<http://ajs.sagepub.com>

High-Energy Extracorporeal Shock Wave Therapy as a Treatment for Insertional Achilles Tendinopathy

John Patrick Furia

Am. J. Sports Med. 2006; 34; 733

DOI: 10.1177/0363546505281810

The online version of this article can be found at:
<http://ajs.sagepub.com/cgi/content/abstract/34/5/733>

Published by:



<http://www.sagepublications.com>

On behalf of:



American Orthopaedic Society for Sports Medicine

Additional services and information for *American Journal of Sports Medicine* can be found at:

Email Alerts: <http://ajs.sagepub.com/cgi/alerts>

Subscriptions: <http://ajs.sagepub.com/subscriptions>

Reprints: <http://www.sagepub.com/journalsReprints.nav>

Permissions: <http://www.sagepub.com/journalsPermissions.nav>

Citations (this article cites 42 articles hosted on the
SAGE Journals Online and HighWire Press platforms):
<http://ajs.sagepub.com/cgi/content/abstract/34/5/733#BIBL>

High-Energy Extracorporeal Shock Wave Therapy as a Treatment for Insertional Achilles Tendinopathy

John Patrick Furia,* MD

From SUN Orthopedics and Sports Medicine, Lewisburg, Pennsylvania

Background: Results of high-energy extracorporeal shock wave therapy for the treatment of insertional Achilles tendinopathy are not determined. It is unclear how local anesthesia alters the outcome of this procedure.

Hypothesis: Extracorporeal shock wave therapy is an effective treatment for insertional Achilles tendinopathy. Local anesthesia field block adversely affects outcome.

Study Design: Case control study; Level of evidence, 3.

Methods: Thirty-five patients with chronic insertional Achilles tendinopathy were treated with 1 dose of high-energy extracorporeal shock wave therapy (ESWT group; 3000 shocks; 0.21 mJ/mm²; total energy flux density, 604 mJ/mm²), and 33 were treated with nonoperative therapy (control group). All extracorporeal shock wave therapy procedures were performed using a local anesthesia field block (LA subgroup, 12 patients) or a nonlocal anesthesia (NLA subgroup, 23 patients). Evaluation was by visual analog score and by Roles and Maudsley score.

Results: One month, 3 months, and 12 months after treatment, the mean visual analog score for the control and ESWT groups were 8.2 and 4.2 ($P < .001$), 7.2 and 2.9 ($P < .001$), and 7.0 and 2.8 ($P < .001$), respectively. Twelve months after treatment, the number of patients with successful Roles and Maudsley scores was statistically greater in the ESWT group compared with the control group ($P > .0002$), with 83% of ESWT group patients having a successful result, and the mean improvement in visual analog score for the LA subgroup was significantly less than that in the NLA subgroup ($F = 16.77$ vs $F = 53.95$, $P < .001$). The percentage of patients with successful Roles and Maudsley scores did not differ among the LA and NLA subgroups.

Conclusion: Extracorporeal shock wave therapy is an effective treatment for chronic insertional Achilles tendinopathy. Local field block anesthesia may decrease the effectiveness of this procedure.

Keywords: tendon injuries; Achilles tendinopathy; extracorporeal shock wave therapy (ESWT)

Disorders of the Achilles tendon are a frustrating cause of posterior heel pain. Achilles tendon injuries occur frequently in runners and jumping athletes and are also common in the general population, particularly in overweight persons.[†] The precise causes and natural history of these injuries remain unknown.[‡]

Intrinsic risk factors include hyperpronation, varus deformity of the forefoot, leg length discrepancy, and limited mobility of the subtalar joint.^{1,3,14,16,25,26,41} Extrinsic risk factors include excessive mechanical overload and training errors such as increased interval training, excessive hill training, and increased mileage.^{3,13,14,16,25,26,41} Other risk

factors include poor technique, fatigue, obesity, and advanced age.^{3,13,14,16,25,26,41}

Maffulli et al²⁰⁻²² have popularized the term *Achilles tendinopathy* to describe the triad of tendon pain, swelling, and impaired performance. From a functional perspective, it is helpful to classify Achilles tendinopathy as insertional, those which occur at the bone-tendon junction, or noninsertional, those that occur more proximally.^{7,25,33} Insertional tendinopathy tends to occur in more active persons, whereas noninsertional tendon injury tends to occur in older, less athletic, and overweight persons.^{7,25,33}

Traditional nonoperative treatment of insertional Achilles tendinopathy consists of rest, anti-inflammatory medications, physical therapy modalities, heel lift orthosis, custom orthosis, and immobilization.^{1-3,23-26,30,40,41,43} In the majority of cases, nonoperative measures are effective.^{1-3,23-26,30,40,41,43}

Surgery for insertional Achilles tendinopathy is reserved for chronic cases. Reports of surgical treatment can be

*Address correspondence to John Patrick Furia, MD, 900 Buffalo Road, Lewisburg, PA 17837 (e-mail: jfuria@ptd.net).

The author has declared a potential conflict of interest: He is the medical director of the orthopedic division of American Kidney Stone Management, Inc.

[†]References 2, 3, 11, 13-15, 17, 20-23, 25, 30, 40-43.

[‡]References 2, 3, 11, 13-15, 17, 20-23, 25, 30, 40-43.

difficult to interpret because of lack of adequate and generally accepted terminology.⁴⁷ Common to all such surgical procedures is a resection of the inflamed retrocalcaneal bursa, excision of the prominent posterolateral bone, and debridement of the calcific and diseased tendon insertion.²⁵ Success rates vary from series to series.^{4,11,21,47} Complications such as delayed wound healing, infection, and tendon avulsion can be troublesome.^{16,21,47} In one series, 25% of patients treated surgically for insertional Achilles tendinopathy were unable to return to their preinjury level of physical activity.²¹ In another series, 2 of 14 patients treated surgically did not obtain pain relief.⁴ For those patients who did improve, the time until pain resolution averaged nearly 12 months.⁴

Extracorporeal shock wave therapy (ESWT) has been used successfully since the late 1980s for the treatment of various musculoskeletal disorders including plantar fasciitis, shoulder calcific tendinitis, lateral epicondylitis, and nonunion of fractures of long bones.⁸ There are now multiple, randomized, double-blinded, clinical trials that support the use of ESWT for plantar fasciitis, lateral epicondylitis, and calcific tendinitis of the shoulder.^{5,10,27,28,35,38,39,45} In contrast, there are only a few reports that have investigated the efficacy of ESWT as a treatment for chronic Achilles tendinopathy.^{19,31,32} None of these pilot studies focused exclusively on the insertional form of Achilles tendinopathy.

Not all reports regarding ESWT have been favorable.^{6,12} One multicenter trial failed to show effectiveness of ESWT compared with placebo ESWT in patients with chronic lateral epicondylitis.¹² A local anesthesia field block was used in this trial.¹² Some authors have suggested that the application of local anesthesia before shock wave therapy reduces the efficiency of low-energy ESWT in patients with chronic plantar fasciitis.³⁸

The purpose of this study was to determine the efficacy of high-energy ESWT for the treatment of adults with chronic insertional Achilles tendinopathy and to determine if the use of a local anesthesia field block had an adverse effect on outcome.

MATERIALS AND METHODS

From June 1, 2003, to January 31, 2004, all patients with an established diagnosis of chronic insertional Achilles tendinopathy who were treated with shock wave therapy by 1 of 8 members of the American Kidney Stone Management-Orthopedics network at 1 of 7 centers were considered for inclusion in the study. A similar group of patients who were treated in the same time interval with additional forms of traditional nonoperative methods (Table 1) but did not receive ESWT (usually because of insurance denial) were enrolled in the control group. Both the ESWT and control groups were derived from the clinical practices of the members of the treatment network. The patients in the control group were selected to match the patients in the ESWT group. Each member used both ESWT and traditional nonoperative methods during the study period.

TABLE 1
Nonoperative Treatments

Rest
Shoeware modifications
Anti-inflammatory medications
Physical therapy
Gastrocnemius-soleus stretching and strengthening
Massage
Ultrasound
Ice
Iontophoresis
Contrast baths
Heel lift orthosis
Custom orthosis
Immobilization

Inclusion Criteria

All patients were evaluated on the basis of a history and a physical examination. The inclusion criteria included patients with an established diagnosis of chronic insertional Achilles tendinopathy for at least 6 months before treatment who had failure with at least 3 forms of traditional nonoperative measures for a minimum of 6 months.

For this study, insertional Achilles tendinopathy was defined as symptoms of moderate to severe posterior heel pain located at the bone-tendon junction that extended no more than 2 cm proximal from the base of the heel, swelling, and impaired function. All patients had anteroposterior and lateral radiographs of the affected ankle that revealed posterior calcaneal spurs or calcifications next to the calcaneus. Magnetic resonance imaging (MRI) scans and additional imaging studies were performed on a case-by-case basis at the discretion of the treating physician.

Exclusion Criteria

Exclusion criteria included rheumatoid arthritis, generalized polyarthritis, Reiter syndrome, local infection, pregnancy, bleeding disorders, tumors, age younger than 18 years, severe endocrine disease, concomitant pain and tenderness in the retrocalcaneal bursa, calcifications in the Achilles tendon, calcifications and/or spurs in the retrocalcaneal bursa area, pain and/or tenderness in the tendon more than 2 cm proximal from the insertion, and advanced peripheral vascular disease. Patients with a history of previous Achilles tendon surgery were also excluded.

ESWT Group

Forty-five patients were treated (47 Achilles tendons). Two patients had both Achilles tendons treated during the study period and were excluded from the data analysis. Four patients underwent concomitant treatment of plantar fasciitis and were also excluded. There was insufficient follow-up data on 4 patients. Thus, 35 patients representing 35 Achilles tendons were available for analysis. These patients represent the ESWT group.

⁸References 5, 9, 10, 27, 28, 35, 36, 38, 39, 45, 46, 50.

TABLE 2
Mean Age and Mean Duration of Symptoms^a

	Age, y			Symptoms, mo		
	Mean	Range	SD	Mean	Range	SD
ESWT group	50	30-67	9.2	19.9	6-60	13
Control group	52.6	21-80	15.9	16.8	7-30	5.2
LA subgroup	52.2	42-67	7.7	19.2	7-36	9.2
NLA subgroup	49	30-65	9.9	20.2	6-60	14.9

^aESWT, extracorporeal shock wave therapy; LA, local anesthesia; NLA, nonlocal anesthesia.

There were 22 women and 13 men in the ESWT group, with a mean patient age of 50 years (range, 30-67 years; SD, 9.2) (Table 2). The mean duration of the condition was 19.9 months (range, 6-60 months; SD, 13) (Table 2). There was no difference in mean age or duration of symptoms between the ESWT and control groups ($P > .2$ for each variable) (Table 2).

ESWT Subgroups

Twelve of the ESWT patients were treated with a local anesthesia field block (LA subgroup), and 23 of the ESWT patients were treated with an anesthesia other than local (NLA subgroup). Some physicians exclusively used a local anesthesia field block in all cases, whereas others used a local anesthesia field block for some patients and another form of anesthesia for other patients. Each treating physician's preference determined the type of anesthesia. The mean patient ages for the LA and NLA subgroups were 52.2 years (range, 42-67 years; SD, 7.7) and 49 years (range, 30-65 years; SD, 9.9), respectively (Table 2). There were 7 women and 5 men in the LA subgroup and 15 women and 8 men in the NLA subgroup. The mean duration of symptoms for the LA and NLA subgroups were 19.2 months (range, 7-36 months; SD, 9.2) and 20.2 months (range, 6-60 months; SD, 14.9), respectively (Table 2). There was also no difference in mean age or duration of symptoms between the LA and NLA subgroups ($P > .8$ for each variable) (Table 2).

Control Group

There were 22 women and 11 men in the control group, with a mean patient age of 52.6 years (range, 21-80 years; SD, 15.9) (Table 2). The mean duration of the condition was 16.8 months (range, 7-30 months; SD, 5.2) for the control group (Table 2). The patients in the control group were managed with traditional nonoperative measures (Table 1) for a minimum of 12 months.

Method of Treatment

All patients signed an informed consent form. The details of the procedure and potential risks were discussed fully before treatment.

All treatments were performed on an outpatient basis using either a local anesthesia field block (12 patients) or a

regional block (23 patients). The choice of the anesthesia was physician and patient dependent. When a local anesthesia was used, the skin and subcutaneous tissues overlying the insertion of the Achilles tendon in the area of intended treatment were anesthetized with approximately 10 mL of a 1% local anesthetic without epinephrine. A member of the anesthesia department administered the ankle blocks and regional anesthesia. Patients treated with ankle blocks or regional anesthesia did not receive supplementation of local anesthesia in the area of treatment.

The ESWT was applied using the Dornier Epos lithotripter (Dornier MedTech Inc, Kennesaw, Ga). The Dornier Epos uses an electromagnetic coil to generate shock waves.⁸ With this device, the shock waves were focused on the area of maximal tenderness beginning at the bone-tendon insertion and extending proximally for a distance of approximately 2 to 3 cm (mean treatment size, 2 cm in length; range, 2-4 cm) as determined on the physical examination. Shock wave application was then guided using ultrasonographic localization of the region of interest.

The procedure was performed with the patient in the lateral decubitus position. The affected ankle was positioned on the targeting device of the Dornier Epos device. Ultrasound gel was applied liberally to the skin overlying the insertion of the Achilles tendon. The shock waves were delivered in a lateral to medial direction, tangential to the Achilles tendon. Prior studies with this shock wave generator have shown that tangential application of shock waves from a lateral to medial direction is well tolerated and has yielded positive results in trials involving patients with plantar fasciitis.^{5,45}

Shock wave application was a dynamic process. The examiner held the affected ankle with both hands and gently and repetitively dorsiflexed, plantar flexed, inverted, and everted the ankle to ensure that the entire insertion of the Achilles tendon as well as the surrounding tissue was treated. The mean size of the area of treatment was approximately 2 to 4 cm in width and 2 to 4 cm in length. The examiner felt the vibrations produced by the shock waves along the medial aspect of the Achilles tendon insertion to confirm adequate depth of penetration.

Eight physicians administered treatments. All physicians followed the exact same treatment protocol. All patients were treated with a single application of shock wave therapy. Each patient was treated with a total of 3000 shocks for a total energy flux density of 604 mJ/mm². Fifty

shocks were given at each power level from 1 through 4 for a total of 200 shocks. The final 2800 shocks were given at power level 5, which corresponds to 0.21 mJ/mm². In no case did the energy level exceed power level 5. The frequency of shock wave application was increased from 60 shocks/min at power level 1 to 240 shocks/min at power level 5.

Postprocedure Treatment

On completion of the procedure, the treated heel was assessed for hematoma, bruising, and swelling. The patients were discharged from the same-day holding area with instructions to rest their heel. Two physicians used a brief period of immobilization (walking boot) as part of their postprocedure protocol. No physician used a cast or a splint. A total of 3 patients were immobilized in a walking boot for a period ranging from 3 to 6 days. No other physician used immobilization. No other cointerventions were used.

Patients were allowed early range of motion and immediate weightbearing activities. If a walking boot was used, it was removed several times per day to allow for early active range of motion exercise. Walking boots were discontinued within 3 to 6 days of the procedure. Activity was advanced as symptoms dissipated. Patients who worked in a sedentary occupation were returned to their pretreatment work status within a week of the procedure. The time to return to sports and heavy labor occupations was made on a case-by-case basis.

Outcome Measures

Outcome measures included visual analog scores (VAS) and the Roles and Maudsley scores. The follow-up examinations were scheduled at 1, 3, and 12 months after treatment. As part of a routine quality and assurance process, all patients were also contacted by a technician via a telephone survey at 1 and 3 months after the procedure. Visual analog scores were collected before treatment, and 1, 3, and 12 months after treatment at the time of the follow-up examination. On the visual analog scale, 10 points indicated severe pain and 0 points indicated no pain.

The Roles and Maudsley scale³⁴ is a subjective 4-point rating scale that has been used by many investigators when reporting results of shock wave therapy. On the scale, 1 point is defined as an excellent result, with the patient having no symptoms. Two points is defined as a good result, with the patient significantly improved from the pretreatment condition and satisfied with the result. Three points is defined as a fair result, with the patient somewhat improved from the pretreatment condition and partially satisfied with the treatment outcome. Four points indicates a poor outcome, with symptoms identical to or worse than the pretreatment condition and with dissatisfaction with the treatment result.

Occupation and Sporting Activities

Twenty-two of the patients in the ESWT and 20 of the patients in the control group stated they participated in some type of regular recreational sporting activity (Table 3).

TABLE 3
Sporting Activities of Extracorporeal Shock Wave Therapy (ESWT) Group and Control Group

	ESWT Group (n = 22)	Control Group (n = 20)
Basketball	3	2
Jogging	5	4
Running	4	2
Volleyball	2	1
Racquetball	3	4
Tennis	2	4
Soccer	1	0
Golf	2	3

TABLE 4
Patient Occupations

	ESWT Group ^a (n = 35)	Control Group (n = 33)
Heavy factory worker	3	2
Manual laborer	1	0
Nurse	6	4
Restaurant server	2	5
Manager	2	0
Teacher	5	7
Flight attendant	0	2
Homemaker	7	4
Office worker	6	7
Student	3	2

^aESWT, extracorporeal shock wave therapy.

Twelve of the ESWT patients and 11 of the control patients worked as laborers, that is, as heavy factory workers or manual laborers, or worked in occupations that required extensive physical activity such as nursing and restaurant service (Table 4).

Statistical Analysis

Statistical analysis was performed using the paired Student *t* test, χ^2 analysis, and 1-way analysis of variance for comparison of the outcome variables. The significance level was $P < .05$. All analyses were conducted using SAS, version 8.2 (SAS Institute, Cary, NC).

RESULTS

The mean age and duration of symptoms for the ESWT and control groups and the LA and NLA subgroups are summarized in Table 2. There was no difference between mean age or mean duration of symptoms between the ESWT and control groups ($P > .8$ for each variable). There was also no difference between mean age or mean duration of symptoms between the LA and NLA subgroups ($P > .8$ for each variable).

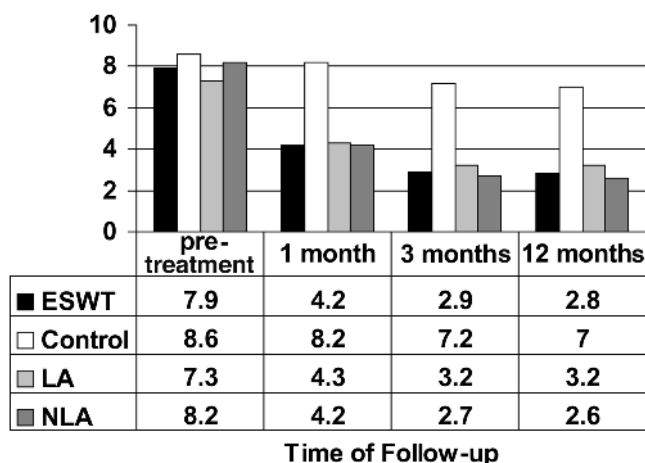


Figure 1. Mean visual analog score for all patients. $P > .05$ for each time point for the control group. $P < .001$ for each time point for the total extracorporeal shock wave therapy (ESWT) group and for the local anesthesia (LA) and nonlocal anesthesia (NLA) subgroups.

ESWT Versus Control Group

Visual Analog Scores. The mean pretreatment VAS for the ESWT group was 7.9 ± 2.0 . One month after treatment, the mean VAS decreased to 4.2 ± 2.4 . This difference was statistically significant ($P < .001$) (Figure 1).

The mean baseline VAS for the control group was 8.6 ± 1.1 . One month after enrollment, the mean VAS was 8.2 ± 1.1 . This difference was not statistically significant ($P > .05$) (Figure 1).

Three months after treatment, the mean VAS for the ESWT group decreased further to 2.9 ± 2.1 ($P < .001$), whereas the corresponding VAS for the control group was 7.2 ± 1.3 , unchanged from the baseline ($P > .05$) (Figure 1).

Twelve months after treatment, the mean VAS for the ESWT group decreased further to 2.8 ± 2.0 ($P < .001$), whereas the corresponding VAS for the control group was 7.0 ± 1.4 ($P > .05$), unchanged from the baseline (Figure 1).

Roles and Maudsley Score. The 1-month, 3-month, and 12-month Roles and Maudsley scores for the ESWT and control groups are summarized in Table 5. At the onset of the study, all ESWT and control patients rated the condition of the affected Achilles tendon as 4 (poor). χ^2 analysis revealed that the number of patients with excellent or good Roles and Maudsley scores, that is, successful results, 1 month, 3 months, and 12 months after treatment was statistically greater in the ESWT group compared with the control group ($P > .0002$ for each time point).

In both the ESWT group and the control group, no patient reported a worsening of symptoms compared with before treatment.

LA Versus NLA Subgroup

Visual Analog Scores. The mean pretreatment VAS for the LA and NLA groups were 7.3 ± 2.3 and 8.2 ± 1.8 , respectively. One month after treatment, the mean VAS for the LA and

NLA groups were 4.3 ± 2.5 ($P < .001$) and 4.2 ± 2.4 ($P < .001$), respectively (Figure 1). Analysis of variance testing revealed that the mean improvement in VAS for the LA subgroup was significantly less than the corresponding gain in the NLA subgroup ($F = 34.76$ vs $F = 48.72$, $P < .001$).

The mean 3-month VAS for the LA and NLA groups were 3.2 ± 2.2 ($P < .001$) and 2.7 ± 2.1 ($P < .001$), both statistically decreased from the pretreatment scores ($P < .001$) (Figure 1). Analysis of variance testing revealed that the mean improvement in VAS for the LA subgroup was significantly less than the corresponding gain in the NLA subgroup ($F = 19.9$ vs $F = 58.79$, $P < .001$).

Twelve months after treatment, the mean VAS for the LA and NLA groups were 3.2 ± 2.2 ($P < .001$) and 2.6 ± 2.2 ($P < .001$), both statistically decreased from the pretreatment score (Figure 1). Analysis of variance testing revealed that the mean improvement in VAS for the LA subgroup was significantly less than the corresponding gain in the NLA subgroup ($F = 16.77$ vs $F = 53.95$, $P < .001$).

Roles and Maudsley Score. The Roles and Maudsley scores for the LA and NLA subgroups are summarized in Table 6. χ^2 analysis revealed no difference in the number of patients with excellent or good Roles and Maudsley scores, that is, successful results, 12 months after treatment among the LA and NLA subgroups ($P > .77$). In both the LA and NLA subgroups, no patient reported a worsening of symptoms compared with before treatment.

Occupation and Sporting Activities

Of the 22 patients in the ESWT group who participated in regular sporting activity, 20 were able to return to their preferred sport. Of the 20 control patients who participated in regular sporting activity, 14 were able to return to their preferred sport. With the number of patients available, there was no difference in return to preferred sporting activity between the ESWT and control groups ($P > .05$). Nine of the 12 ESWT patients and 6 of the 11 control patients who worked as laborers or in occupations that required extensive physical activity were able to return to their preinjury occupations.

Effects of Immobilization

Three of the ESWT patients were briefly immobilized after the procedure. The mean 1-month, 3-month, and 12-month VAS for these patients were 4.0 ± 2.0 , 3.0 ± 2.1 , and 2.9 ± 2.3 , respectively. At 12 months after treatment, 2 of these patients were rated as good and 1 patient was rated as fair. With the numbers available, it was impossible to make meaningful comparisons between these patients and the control group.

Complications

There were only 5 minor complications. Two patients had pain during the treatment. The pain resolved after completion of the procedure. Two patients had transitory reddening

TABLE 5
Summary of Roles and Maudsley Scores for Extracorporeal Shock Wave Therapy (ESWT) and Control Groups

	1 Month				3 Months				12 Months			
	ESWT (n = 35)		Control (n = 33)		ESWT (n = 35)		Control (n = 33)		ESWT (n = 35)		Control (n = 33)	
	n	%	n	%	n	%	n	%	n	%	n	%
1, excellent	6	17	2	6	6	17	2	6	6	17	2	6
2, good	7	20	10	30	23	66	11	33	23	66	11	33
3, fair	18	51	15	45	3	9	15	45	3	9	15	45
4, poor	4	11	6	18	3	9	5	15	3	9	5	15

TABLE 6
Summary of Roles and Maudsley Scores for Local Anesthesia (LA) and Nonlocal Anesthesia (NLA) Subgroups

	1 Month				3 Months				12 Months			
	LA (n = 12)		NLA (n = 23)		LA (n = 12)		NLA (n = 23)		LA (n = 12)		NLA (n = 23)	
	n	%	n	%	n	%	n	%	n	%	n	%
1, excellent	0	0	6	26	0	0	6	26	0	0	6	26
2, good	2	17	3	13	9	75	14	61	10	83	14	61
3, fair	7	58	13	57	1	8	2	9	1	8	2	9
4, poor	3	25	1	4	2	17	1	4	1	8	1	4

of the skin that resolved without intervention. One patient developed transitory numbness on the plantar aspect of the heel that resolved within 24 hours without treatment.

DISCUSSION

There is currently no consensus as to the best method to treat insertional Achilles tendinopathy. Interventions such as anti-inflammatory medications, heel lift orthosis, custom orthosis, gastrocnemius-soleus stretching and strengthening, contrast baths and other physical therapy modalities, and immobilization are routinely used to treat this condition.¹¹ Unfortunately, there are little data to support the use of many of these therapeutic measures.^{25,42}

In contrast, ESWT has been shown in several randomized, placebo-controlled studies to be an effective treatment for various orthopaedic conditions.¹¹ Basic science studies on rabbit Achilles tendons performed by Rompe et al³⁷ have shown that with proper dosing, ESWT can be safely applied to the Achilles tendon. In a histologic study, Rompe et al³⁷ showed that there was no irreversible damage to the tendon and adjacent tissues of rabbits treated with energy flux densities up to 0.28 mJ/mm² and that any minor changes completely reversed within 4 weeks after treatment.

Pilot studies investigating the effects of ESWT on Achilles tendinopathy have been promising. Lohrer et al¹⁹ reported significant pain reduction and increased functionality in patients with both insertional and noninsertional Achilles tendinopathy who were treated with radial shock wave therapy. However, there was no control group.

Perlick et al³² compared ESWT with surgery (open debridement of diseased tendon with or without bone spur removal) as a treatment for chronic Achilles tendinopathy. At 1-year follow-up, there was a statistically significant reduction in pain using VAS in both groups: from 73 to 38 and from 70 to 28 in the ESWT and operative groups, respectively.³² However, there was no differentiation between insertional and noninsertional types of Achilles tendinopathy.

In a small randomized, double-blinded, placebo-controlled trial consisting of 39 patients, Peers³¹ reported his experience using low-energy ESWT for the treatment of patients with chronic Achilles tendinopathy. ESWT was administered in 3 sessions at 1-week intervals using 1000 impulses, at an energy flow density of 0.2 mJ/mm² and a frequency of 4 Hz.³¹ At 12-week follow-up, the 20 treated patients had significantly improved VAS when compared with an untreated control group. A 77% success rate was reported.³¹ There was also no differentiation between insertional and noninsertional forms of Achilles tendinopathy in this study.

The present study evaluated the effects of high-energy shock wave therapy on a consecutive series of patients with chronic insertional Achilles tendinopathy who had not responded to nonoperative management. The outcome for the entire study population was evaluated and compared

¹¹References 11, 13, 14, 21, 24, 25, 42, 43, 46.

¹¹References 5, 10, 27, 28, 35, 36, 38, 39, 45.

with a control group. The effect of application of local anesthesia was analyzed.

The mean VAS for the ESWT group was statistically improved at 1, 3, and 12 months after treatment compared with the control group. The percentages of excellent or good results using the Roles and Maudsley score at 12 months after the procedure for the ESWT and control groups were 82.9% and 39.4%, respectively. There were no significant complications, and no patient required additional shock wave therapy.

Rompe et al³⁸ in a randomized, prospective trial compared the results of low-energy ESWT without local anesthesia with low-energy ESWT performed with local anesthesia. At 3 months after treatment, 67% of patients who had ESWT without local anesthesia achieved $\geq 50\%$ reduction of heel pain, compared with 29% of patients who had ESWT with local anesthesia ($P < .001$).³⁸

In the current study, when considering improvement in VAS, it appears that the use of a local anesthesia field block decreased the effectiveness of the high-energy ESWT procedure. At 1, 3, and 12 months after treatment, the mean improvement in VAS for the LA subgroup was significantly less than the corresponding gain noted in the NLA subgroup. It remains unclear why this is so.

One theory is that infiltration of a local anesthesia before an ESWT procedure interferes with the focusing and targeting of the shock waves on the area of maximal discomfort. There are 2 reasons why this theory is unlikely to account for the results in this trial. First, the area of maximal discomfort was identified before treatment. Second, the NLA group also received a form of anesthesia that would preclude feedback during shock wave application.

Takahashi et al,⁴⁴ in an animal model, have demonstrated that the application of low-energy shock waves decreases calcitonin gene-related peptide immunoreactivity in sensory neurons. Ohtori et al²⁹ have shown that low-energy shock wave application (1000 impulses; energy flux density, 0.08 mJ/mm^2) to rat skin induces degeneration and reinnervation of sensory nerve fibers. Application of local anesthesia may alter the concentration and release of neuropeptides, which in some way may interfere with the neurogenic inflammatory response and antinociceptive effects associated with ESWT.^{18,29,44}

Animal models have also demonstrated increased neovessel formation and enhanced angiogenesis in tissues treated with shock wave therapy,^{48,49} which is presumably another mechanism of action of ESWT.^{48,49} The use of local anesthesia may alter the inflammatory response invoked by ESWT and, by so doing, reduce the degree of neovascularization.^{48,49}

It should be noted that there was no difference in the percentage of excellent or good results using the Roles and Maudsley score at 12 months after the procedure between the LA and NLA subgroups. Obviously, further clinical and basic science work is needed to prove or disprove the above-mentioned theories.

Extracorporeal shock wave therapy is an emerging technology, and protocols vary from trial to trial. The different modes of delivery of the shock waves, single treatment versus multiple treatments and low-energy versus high-energy, and the method of generating the shock

waves, electrohydraulic versus electromagnetic, can all influence the outcome of the therapy.

The single-treatment, high-energy protocol used in this trial is a modification of the protocol used in prior studies with this device.^{5,45} In no instance did the energy flux density exceed 0.28 mJ/mm^2 , and there were no significant complications. However, the results of ESWT are only valid for the therapeutic parameters applied. For this reason, results from this trial cannot be extrapolated to other ESWT treatment protocols or devices.

This study is a retrospective cohort study and, as such, has some inherent weaknesses. This series represents a relatively large number of subjects compared with other clinical trials involving ESWT and insertional Achilles tendinopathy. However, when considering the number of subjects in each subgroup, the absolute numbers are relatively small. The length of follow-up was only 12 months; however, a positive effect was already evident at this time. Finally, MRI scans were not performed for each patient. However, the symptoms used to define insertional Achilles tendinopathy, the combination of insertional pain within 2 cm of the heel, swelling, and loss of function, are now generally accepted and considered to be appropriate descriptors of this condition.^{22,42}

Nonetheless, this series contributes valuable information. To my knowledge, this study is the first investigation involving ESWT and chronic Achilles tendinopathy limited entirely to the insertional form of this condition. The data from this study demonstrate that ESWT is a safe and effective procedure that can be used to treat patients with chronic insertional Achilles tendinopathy. This positive treatment effect may be compromised by application of a local anesthesia to the painful area before ESWT. Further prospective studies are needed to confirm these findings.

REFERENCES

1. Alfredson H, Lorentzon R. Chronic Achilles tendinosis: recommendations for treatment and prevention. *Sports Med.* 2000;29:135-146.
2. Almekinders LC. Tendinitis and other chronic tendinopathies. *J Am Acad Orthop Surg.* 1998;6:157-164.
3. Baxter DE, Zingas C. The foot in running. *J Am Acad Orthop Surg.* 1995;3:136-145.
4. Boberg JS, Anania MC. Retrocalcaneal exostosis: anatomy and a new surgical approach. *J Am Podiatr Med Assoc.* 2002;92:537-542.
5. Buch M, Knorr U, Fleming L, et al. Shock wave therapy for the treatment of chronic plantar fasciitis. *Orthopade.* 2002;31:637-644.
6. Buchbinder R, Ptasznik R, Gordon J, Buchanan J, Prabaharan V, Forbes A. Ultrasound-guided extracorporeal shock wave therapy for plantar fasciitis. *JAMA.* 2002;288:1364-1372.
7. Clain MR, Baxter DE. Achilles tendinitis. *Foot Ankle.* 1992;13:482-487.
8. Dornier MedTech Inc. *Dornier Epos Ultra: Summary of Safety and Effectiveness Data.* Kennesaw, Ga: Dornier MedTech Inc; 2002.
9. Furia JP. Safety and efficacy of extracorporeal shock wave therapy for chronic lateral epicondylitis. *Am J Orthop.* 2005;24:13-19.
10. Gerdesmeyer L, Wagenpfeil S, Haake M, et al. Extracorporeal shock wave therapy for the treatment of chronic calcifying tendonitis of the rotator cuff: a randomized controlled trial. *JAMA.* 2003;290:2573-2580.
11. Gerken AP, McGarvey WC, Baxter DE. Insertional Achilles tendinitis. *Foot Ankle Clin.* 1996;1:337-248.
12. Haake M, Konig IR, Decker T, Riedel C, Buch M, Muller HH. Extracorporeal shock wave therapy for the treatment of lateral epicondylitis: a randomized multicenter trial. *J Bone Joint Surg Am.* 2002;84:1982-1991.

13. James SL, Bates BT, Osternig LR. Injuries to runners. *Am J Sports Med.* 1978;6:40-50.
14. Jones DC. Achilles tendon problems in runners. *Instr Course Lect.* 1998;47:419-427.
15. Jones DC, James SL. Overuse injuries of the lower extremity: shin splints, iliotibial band friction syndrome, and exertional compartment syndromes. *Clin Sports Med.* 1987;6:273-290.
16. Kolodziej P, Glisson RR, Nunley JA. Risk of avulsion of the Achilles tendon after partial excision for treatment of insertional tendonitis and Haglund's deformity. *Foot Ankle Int.* 1999;20:433-437.
17. Kvist M. Achilles tendon injuries in athletes. *Sports Med.* 1994;18:173-201.
18. Lee J, Emerson RB. Alterations in neurogenic inflammatory responses in mice lacking CGRP. *Scientific WorldJournal.* 2001;18:1-7.
19. Lohrer H, Scholl J, Arentz S. Achillodynie und patellaspixensyndrom-ergebnisse der behandlung austerapiertes, chronischer falle mit radiale stobwellen. *Sportveri sportschad.* 2002;16:108-114.
20. Maffulli N, Khan KM, Puddu G. Overuse tendon conditions: time to change a confusing terminology. *Arthroscopy.* 1998;14:840-843.
21. Maffulli N, Testa V, Capasso G, Sullo A. Calcific insertional Achilles tendinopathy. *Am J Sports Med.* 2004;32:174-182.
22. Maffulli N, Wong J, Almekinders LC. Types and epidemiology of tendinopathy. *Clin Sports Med.* 2003;22:675-692.
23. McCrory JL, Martin DF, Lowery RB, et al. Etiologic factors associated with Achilles tendinitis in runners. *Med Sci Sports Exerc.* 1999;31:1374-1381.
24. McGarvey WC, Palumbo RC, Baxter DE, Leibman BD. Insertional Achilles tendinosis: surgical treatment through a central tendon splitting approach. *Foot Ankle Int.* 2002;23:19-25.
25. Myerson M, McGarvey W. Disorders of the Achilles insertion and Achilles tendinitis. *Instr Course Lect.* 1999;48:211-218.
26. Nigg BM. The role of impact forces and foot pronation: a new paradigm. *Clin J Sport Med.* 2001;11:2-9.
27. Ogden JA, Alvarez RG, Levitt RL, Johnson JE, Marlow ME. Electrohydraulic high-energy shock-wave treatment for chronic plantar fasciitis. *J Bone Joint Surg Am.* 2004;86:2216-2228.
28. Ogden JA, Alvarez RG, Levitt R, Marlow M. Shock wave therapy for chronic plantar fasciitis. *Clin Orthop Relat Res.* 2001;387:47-59.
29. Ohtori S, Inoue G, Mannoji C, et al. Shock wave application to rat skin induces degeneration and reinnervation of sensory nerve fibers. *Neurosci Lett.* 2001;315:57-60.
30. Paavola M, Kannus P, Jarvinen TA, Khan K, Jozsa L, Jarvinen M. Current concepts review: Achilles tendinopathy. *J Bone Joint Surg Am.* 2002;84:2062-2076.
31. Peers K. *Extracorporeal Shock Wave Therapy in Chronic Achilles and Patellar Tendinopathy.* Leuven, Belgium: Leuven University Press; 2003.
32. Perlick L, Schiffmann R, Kraft CN, Walny T, Diedrich O. Die extrakorporelle stobwellentherapie bei der chronischen Achillodynie. Experimentelle untersuchungen und vorlaufige klinische ergebnisse. *Z Orthop.* 2002;140:275-280.
33. Puddu G, Ippolito E, Postacchini F. A classification of Achilles tendon disease. *Am J Sports Med.* 1976;4:145-150.
34. Roles NC, Maudsley RH. Radial tunnel syndrome: resistant tennis elbow as a nerve entrapment. *J Bone Joint Surg Br.* 1972;54:499-508.
35. Rompe JD, Decking J, Schoellner C, Theis C. Repetitive low-energy shock wave treatment for chronic lateral epicondylitis in tennis players. *Am J Sports Med.* 2004;32:734-743.
36. Rompe JD, Hopf C, Kullmer K, Heine J, Burger R. Analgesic effects of extracorporeal shock wave therapy chronic tennis elbow. *J Bone Joint Surg Br.* 1996;78:233-237.
37. Rompe JD, Kirkpatrick CJ, Kullmer K, Schwitalle M, Krschek O. Dose-related effects of shock waves on rabbit tendo Achilles. *J Bone Joint Surg Br.* 1998;80:546-552.
38. Rompe JD, Meurer A, Nafe B, Hofmann A, Gerdesmeyer L. Repetitive low-energy shock wave application without local anesthesia is more efficient than repetitive low-energy shock wave application with local anesthesia in the treatment of chronic plantar fasciitis. *J Orthop Res.* 2005;23:931-941.
39. Rompe JD, Schoellner C, Nafe B. Evaluation of low energy extracorporeal shock wave treatment for treatment of chronic plantar fasciitis. *J Bone Joint Surg Am.* 2002;84:335-341.
40. Saltzman CL, Tearse DS. Achilles tendon injuries. *J Am Acad Orthop Surg.* 1998;6:316-325.
41. Schepsis AA, Jones H, Haas AL. Achilles tendon disorders in athletes. *Am J Sports Med.* 2002;30:287-304.
42. Sharma P, Maffulli N. Current concepts review tendon injury and tendinopathy: healing and repair. *J Bone Joint Surg Am.* 2005;87:187-2002.
43. Sorosky B, Press J, Plastaras C, Rittenburg J. The practical management of Achilles tendinopathy. *Clin J Sport Med.* 2004;14:40-44.
44. Takahashi N, Wada Y, Ohtori S, Saisu T, Moriya H. Application of shock waves to rat skin decreases calcitonin gene-related peptide immunoreactivity in dorsal root ganglion neurons. *Auton Neurosci.* 2003;107:81-84.
45. Theodore GH, Buch M, Amendola A, Bachman C, Fleming LL, Zingas C. Extracorporeal shock wave therapy for the treatment of plantar fasciitis. *Foot Ankle Int.* 2004;25:290-297.
46. Valchanou VD, Michailov P. High energy shock wave in the treatment of delayed and nonunion of fractures. *Int Orthop.* 1991;15:181-184.
47. Vulpiani MC, Guzzini M, Ferretti A. Operative treatment of chronic Achilles tendinopathy. *Int Orthop.* 2003;27:307-310.
48. Wang CJ, Huang HY, Pai CH. Shock wave enhances neovascularization at the tendon-bone junction. *J Foot Ankle Surg.* 2002;41:16-22.
49. Wang CJ, Wang FS, Yang KD, Huang CS, Hsu CC, Yang LC. Shock wave therapy induces neovascularization at the tendon-bone junction: a study in rabbits. *J Orthop Res.* 2003;21:984-989.
50. Wang CJ, Yang KD, Wang FS. Shock wave therapy for calcific tendinitis of the shoulder. *Am J Sports Med.* 2003;31:425-430.